



Specialty Services

## Telectyology

Clinical Pathology in your practice... on demand! Wield the power of digital telectyology with board certified clinical pathologists across the globe.


24/7/365 availability

Comprehensive reports in minutes

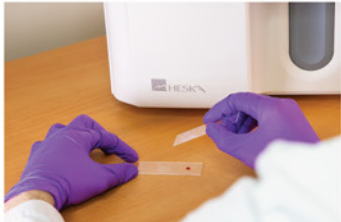"Right Meow" STAT service

Real-time chat support

Board-certified clinical pathologists



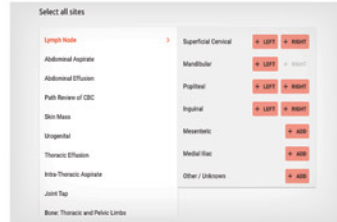
# Easy Operation



**1 Obtain sample. Stain with Diff Quik**



**2 Place prepared slide into scanner**



**3 Enter patient and site information**



**Pathologist review and report**

## The HeskaView™ Digital Telecytology Advantage

Provide better diagnosis and treatment for difficult or time-consuming cases.

- Elevate standard of patient care
- Expedite client communication
- Eliminate delays in slide review
- Move on to next step diagnostics and treatment same day



### Turn-around time priorities...

**NORMAL PRIORITY**

✓ TURNAROUND AVERAGE: **5 hours**

**HIGH PRIORITY**

✓ TURNAROUND AVERAGE: **2 hours**

**RIGHT MEOW**

✓ TURNAROUND AVERAGE: **15 minutes\***

## Add a specialty service to your practice without hiring a specialist!

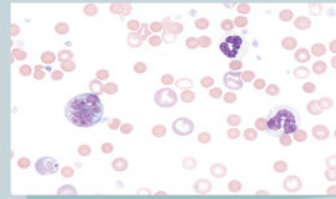
Digital telecytology allows timely access to veterinary clinical pathologists who can assist with diagnostic evaluation of your patients. Whether you are a cytology novice or expert, the board-certified pathologists at HeskaView Specialty Services can help with everything from CBC pathology review to presurgical planning, and more...

**Start diagnosing at the speed of digital today.**

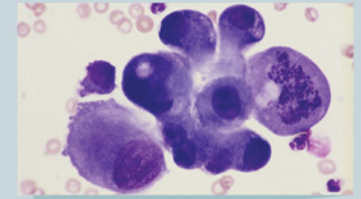
### Examples of Submissions

Blood Smears  
Fine Needle Aspirates  
Body Cavity Effusions  
Bone Marrow Aspirates  
and more...

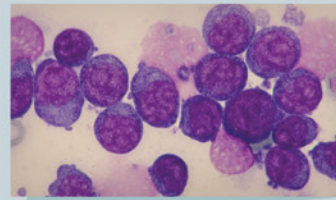
## Get answers to difficult and time-consuming cases



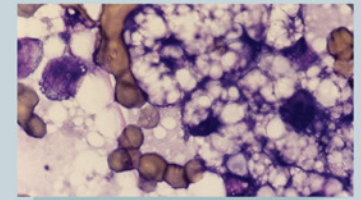
**Image source:** 4 year old M/C Cocker Spaniel; peripheral blood film; **Immune mediated hemolytic anemia?**



**Image source:** 12 year old F/S cat; 1.5 cm diameter mass near the angle of the jaw; **Cancer or inflammation?**



**Image source:** 6 year old M/C GSD; 3.5 cm soft mass in submandibular; **Lymphadenitis, lymphoma or a sialocele?**



**Image source:** 8 year old F/S cat; hepatomegaly and increased liver enzymes; **Hepatic lipodosis or cancer?**

