



TELECYTOLOGY

Specialty Services

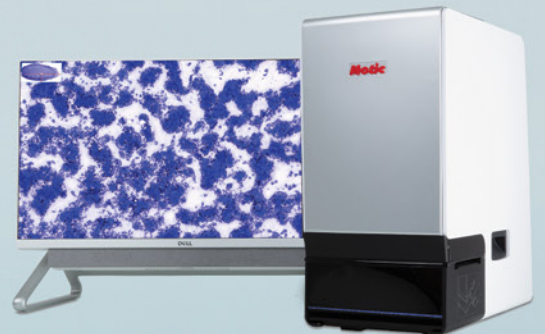
Clinical Pathology in your practice... on demand! Wield the power of digital telecytology with our global team of board-certified clinical pathologists.

Comprehensive reports in minutes

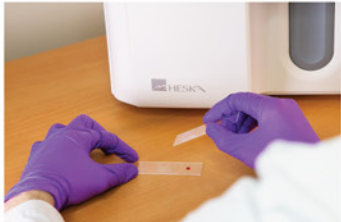"Right Meow" STAT service

Real-time chat support

Board-certified clinical pathologists



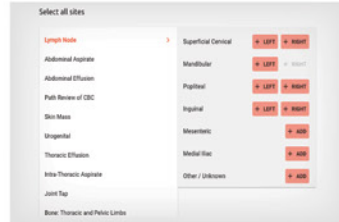
Easy Operation



1 Obtain samples and stain with Diff Quik



2 Place prepared slide into scanner



3 Enter patient and site information



Pathologist review and report

The HeskaView™ Telecytology Advantage

- Elevate standard of patient care
- Expedite client communication
- Eliminate delays in slide review
- Move on to next step diagnostics and treatment same day



Turn-around time options...

NORMAL PRIORITY

✓ TURNAROUND AVERAGE: **5 hours**

HIGH PRIORITY

✓ TURNAROUND AVERAGE: **2 hours**

RIGHT MEOW

✓ TURNAROUND AVERAGE: **15 minutes***

Add a specialty service to your practice without hiring a specialist!

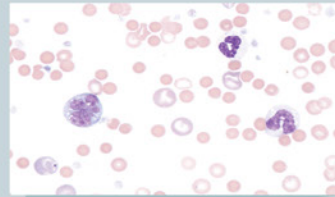
Digital telecytology allows timely access to veterinary clinical pathologists who can assist with diagnostic evaluation of your patients. Whether you are a cytology novice or expert, the board-certified pathologists at HeskaView Specialty Services can help with everything from blood smears to fine needle aspirates to pre-surgical planning and more.

Examples of Submissions

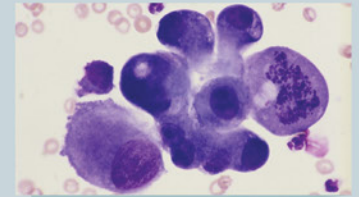
- CBC Pathology Review
- Dermal & Subcutaneous Masses
- Lymph Nodes
- Body Cavity Effusions
- Joint Taps
- Oral & Nasal Masses
- Abdominal Organs & Masses
- Thoracic Organs & Masses
- BAL/TTW
- Urogenital Cytology
- Vaginal Cytology
- Bone Lesions
- Bone Marrow Cytology
- CSF Cytology and more...

Start diagnosing at the speed of digital today.

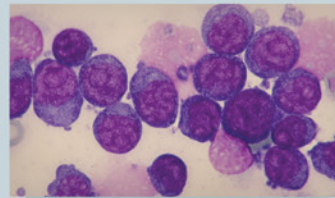
Get answers to difficult and time-consuming cases



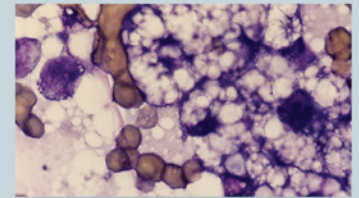
4 year old M/C Cocker Spaniel – peripheral blood film:
Immune mediated hemolytic anemia?




12 year old F/S DSH – 1.5 cm round, firm mass near the angle of the jaw:
Cancer or inflammation?



6 year old M/C GSD – 3.5 cm round, soft mass in submandibular space:
Lymphadenitis, lymphoma, or sialocele?



8 year old F/S DSH – hepatomegaly and increased liver enzymes:
Hepatic lipidosis or cancer?



*For preliminary interpretation, when available. Additional STAT charges apply.