



TELECYTOLOGY

## Specialty Services

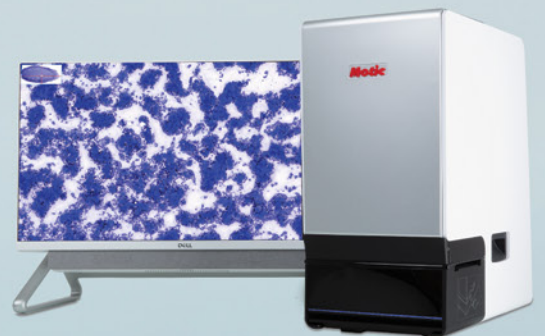Clinical Pathology in your practice... on demand! Wield the power of digital telecytology with our global team of board-certified clinical pathologists.

Comprehensive reports in minutes

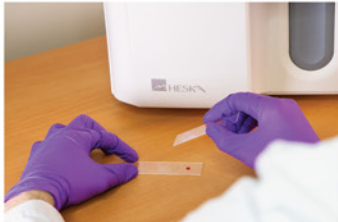STAT service

Real-time chat support

Board-certified clinical pathologists



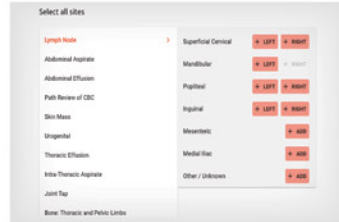
## Easy Operation



1 Obtain samples and stain with Diff Quik



2 Place prepared slide into scanner



3 Enter patient and site information



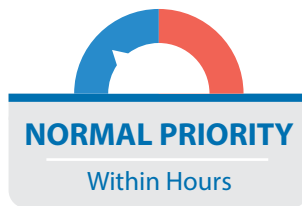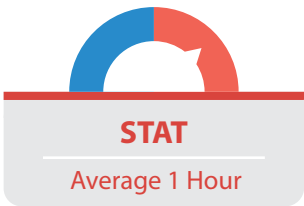
Pathologist review and report

## The HeskaView Telecytology™ Advantage

- Elevate standard of patient care
- Expedite client communication
- Eliminate delays in slide review
- Move on to next step diagnostics and treatment same day



## Turn-around time options...



## Add a specialty service to your practice without hiring a specialist!

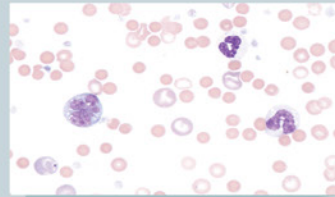
Digital telecytology allows timely access to veterinary clinical pathologists who can assist with diagnostic evaluation of your patients. Choose STAT\* or Normal Priority<sup>§</sup> turn-around time options. Whether you are a cytology novice or expert, the board-certified pathologists at HeskaView Specialty Services can help with everything from blood smears to fine needle aspirates to pre-surgical planning and more.

### Examples of Submissions

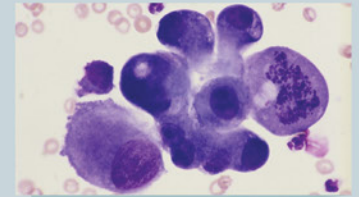
- CBC Pathology Review
- Dermal & Subcutaneous Masses
- Lymph Nodes
- Body Cavity Effusions
- Joint Taps
- Oral & Nasal Masses
- Abdominal Organs & Masses
- Thoracic Organs & Masses
- BAL/TTW
- Urogenital Cytology
- Vaginal Cytology
- Bone Lesions
- Bone Marrow Cytology
- CSF Cytology and more...

Start diagnosing at the speed of digital today.

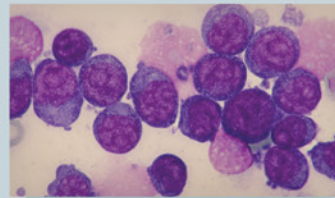
## Get answers to difficult and time-consuming cases



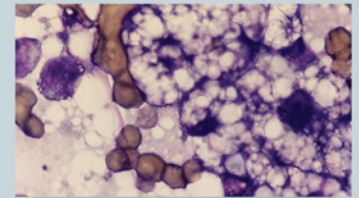
4 year old M/C Cocker Spaniel – peripheral blood film:  
**Immune mediated hemolytic anemia?**



12 year old F/S DSH – 1.5 cm round, firm mass near the angle of the jaw:  
**Cancer or inflammation?**



6 year old M/C GSD – 3.5 cm round, soft mass in submandibular space:  
**Lymphadenitis, lymphoma, or sialocele?**



8 year old F/S DSH – hepatomegaly and increased liver enzymes:  
**Hepatic lipidosis or cancer?**



\*For preliminary interpretation. Additional STAT charges apply. <sup>§</sup>Average turnaround times may vary. Longer turnaround times may be experienced during peak submission times, overnights and on weekends. ©2023 Heska Corporation. All Rights Reserved. Specifications and appearance may be changed without notice. Motic is a registered trademark of Motic Instruments Inc. HESKA is a registered trademark and HeskaView Telecytology is a trademark of Heska Corporation in the United States and in other countries. US21L10204\_007